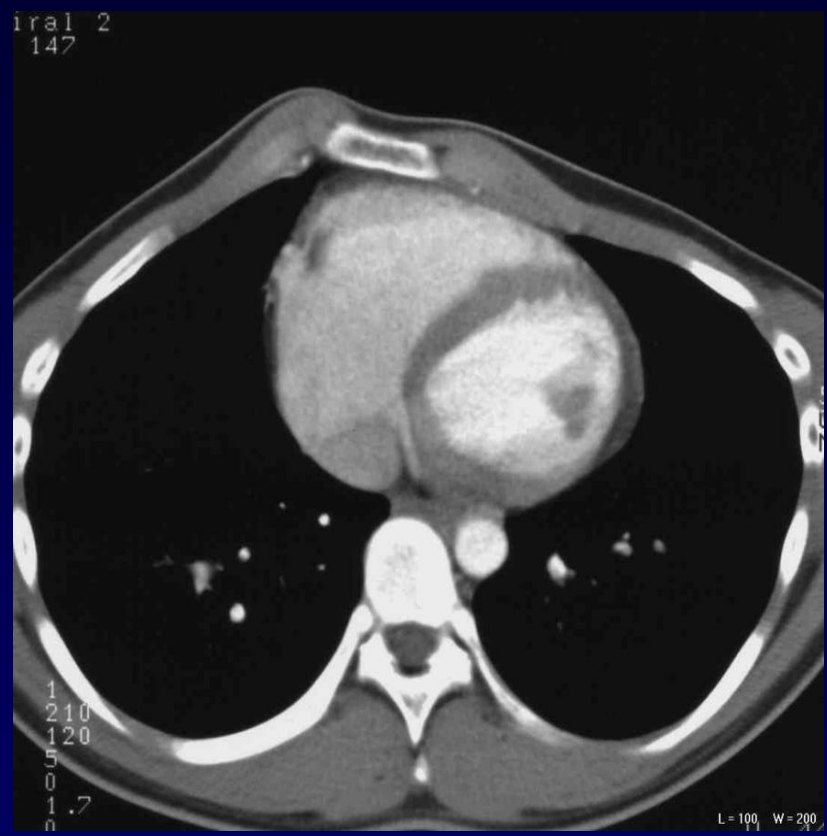
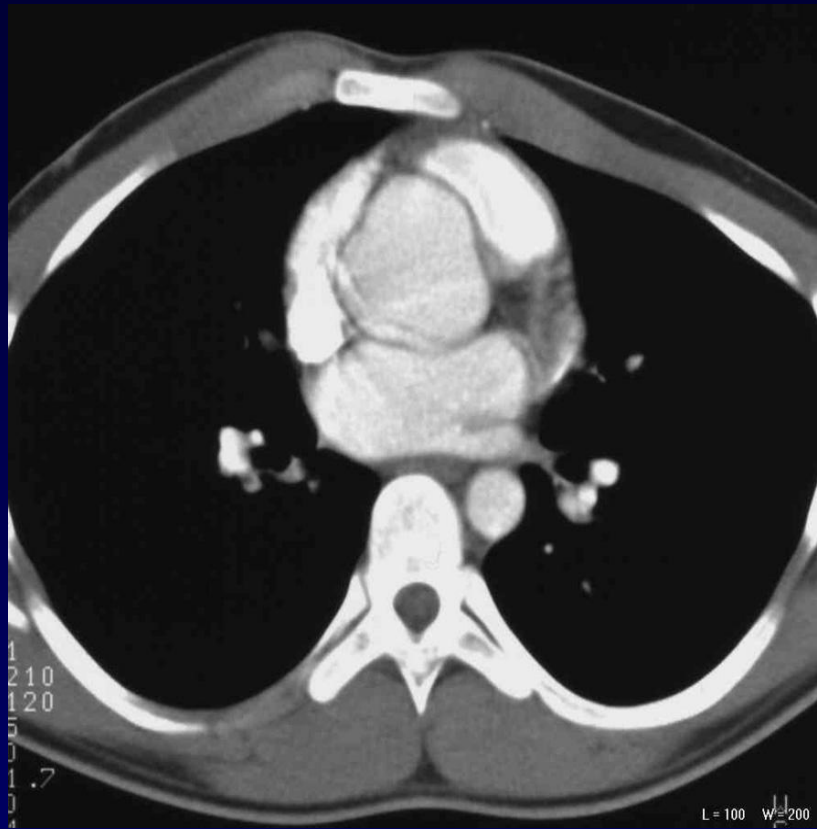
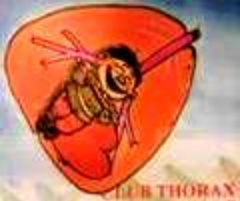
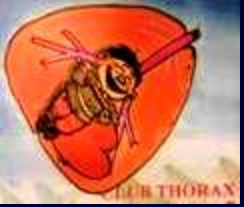


L. METGE

Homme de 18 ans

Bilan de douleurs thoraciques





Diagnostic ?



ECTASIE DE L'AORTE ASCENDANTE

DEFORMATION THORACIQUE